

## COMPLETE DENTURE WITH METAL DENTURE BASE: A CASE REPORT.

**Vishrut Shah\*, Sunil Dhaded\*\***

**\* Post Graduate Student**

**\*\* Professor and Head**

**A.ME.S Dental College ,Raichur -584101**

---

### **Abstract:**

*Polymethyl methacrylate exhibits excellent physical properties. Unfortunately, complete dentures fabricated from this material may still fracture. The fracture of acrylic resin dentures is an unresolved problem in Prosthodontics. Metal framework reinforcement is used in complete dentures to improve the fracture resistance, dimensional stability, accuracy, weight, and retention of a definitive prosthesis. A potential method of preventing this fracture is metal reinforcement of the palatal portion of the prosthesis. A technique will be presented describing a sequence that incorporates predictable design, fabrication and finishing of a metal palate for a maxillary complete denture.*

---

### **Introduction:**

The most commonly used material to make complete denture in clinical Prosthodontic practice is acrylic resin.<sup>1</sup> However fracture of acrylic denture base is occasionally an avoidable complication because the mechanical properties of acrylic resin may not be sufficient to withstand masticatory stress.<sup>2-4</sup> Jagger et al. reported that despite the popularity of acrylic at satisfying aesthetic demands, it is still far from ideal and fulfilling the mechanical requirement of prosthesis.<sup>4</sup>

There is a greater risk of fracture of the acrylic denture, if the thickness of denture base is less or minimal. To overcome this problem, acrylic denture base can be made with cast metal denture base.<sup>5</sup>

They are stronger, have greater resistance to fatigue and are less likely to break under normal conditions.<sup>6</sup>

Complete dentures (CD) reinforced with metal bases (framework) (MB) are occasionally used in rehabilitation of edentulous patients, particularly in cases where there is a risk of fracture.

Certain investigations have proved metal framework to be effective in reducing fungal growth typically present in complete dentures.

**Case report:**

An 83 year old male patient reported to department of Prosthodontics with a chief complaint of fractured lower denture in the midline region and attrited teeth in the upper metal denture base and patient wanted a new set of dentures.

**Procedure:**

On examination, patient had class I ridge relation, with normal inter arch (20mm) space, midline fracture of lower denture extending from the interdental region between lower central incisors till denture flange area and attrited teeth in the upper metal denture (fig 1). Lower denture was temporarily stabilized with self cure acrylic resin.

Primary impression was made by using denture with elastomeric impression material. (fig 2) Cast was poured with plaster of Paris, custom tray was fabricated and border moulding was performed with low fusing type I impression compound (green stick). The final wash impression was made with low viscosity zinc oxide eugenol impression paste. Master cast was poured with dental stone.

Duplication of master cast was done by using reversible hydrocolloid (AGAR) impression material and poured with refractory material. Wax pattern was made on refractory cast, (fig 3) invested with phosphate bonded investment material and casting was done.

Wax pattern was made for denture base, (fig 4) flasking, dewaxing and packing done with heat cure acrylic resin. (fig 5) Wax occlusal rim was made and Jaw relation was carried out conventionally to record vertical and centric relation. (fig 6)

Teeth arrangement was done in a conventional manner in class I molar relation. Try in was done (fig 7) and acrylization of denture done with heat cure acrylic resin. Denture insertion was carried out.(fig 8) Post insertion instructions were given regarding denture maintenance and oral hygiene.

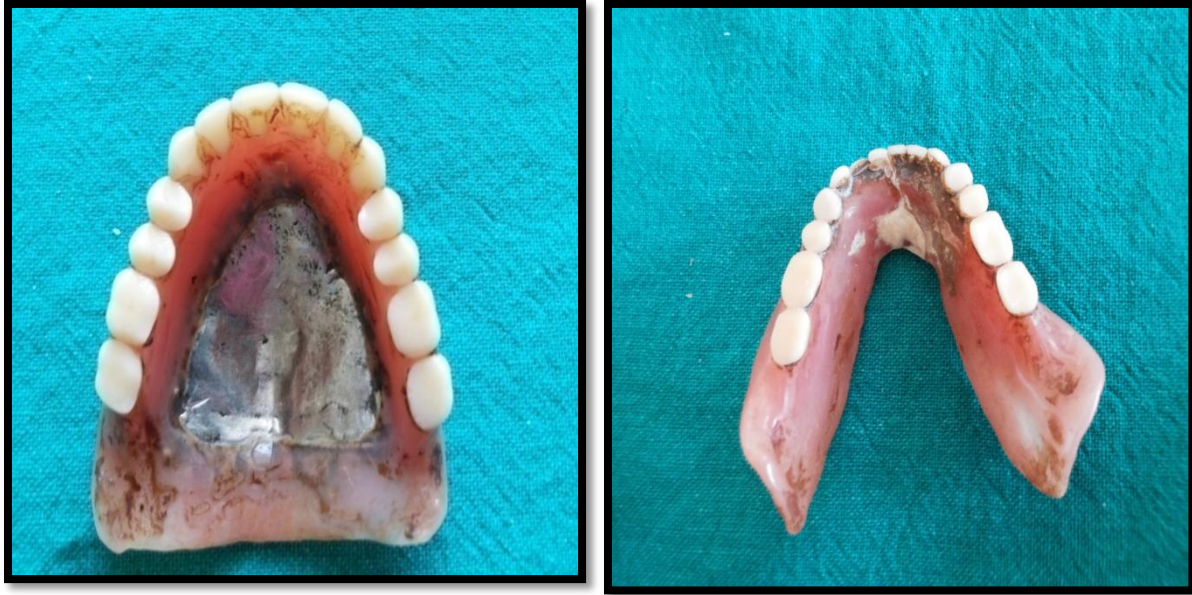

Figure 1: Attrited teeth in upper denture and midline fracture of lower denture extending from interdental region of central incisor to flange area.



Figure 2: Primary impression made with elastomeric impression material



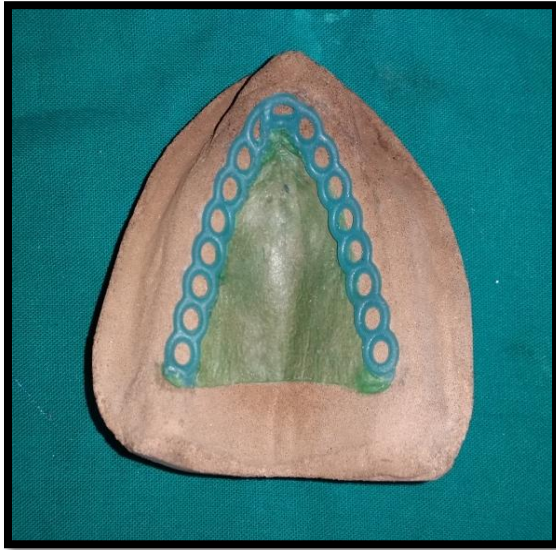


Figure3: Wax pattern for metal framework with casting wax 0.5 mm extending to crest of the ridge with retentive hole for metal and acrylic resin.

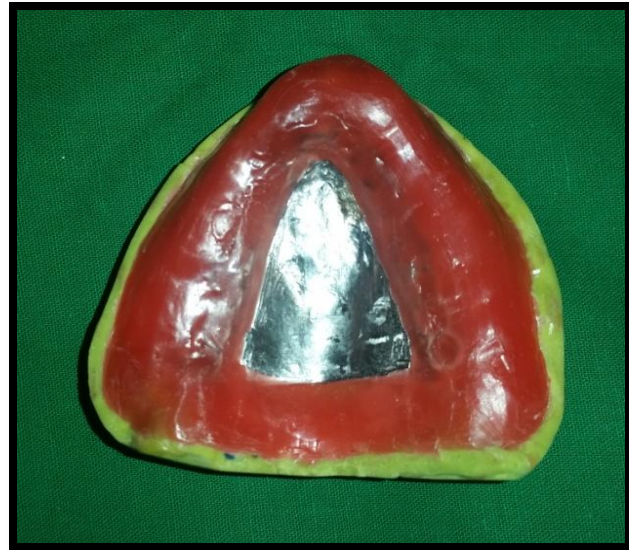

Figure4: Metal base and wax for smooth denture base

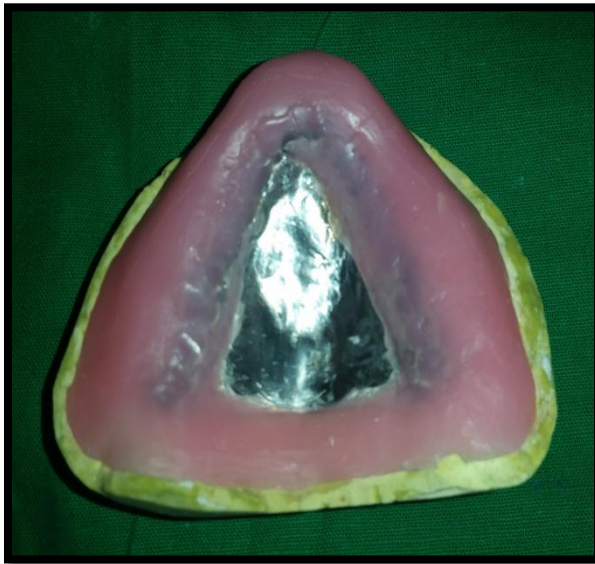

Figure5: Metal denture base

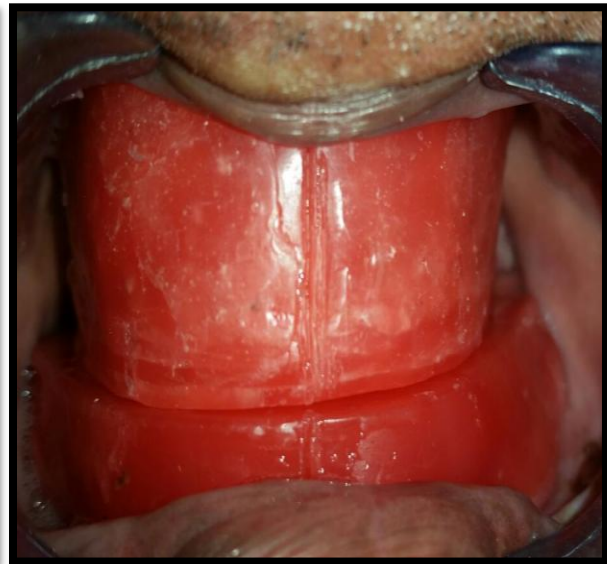


Figure6: Jaw relation done

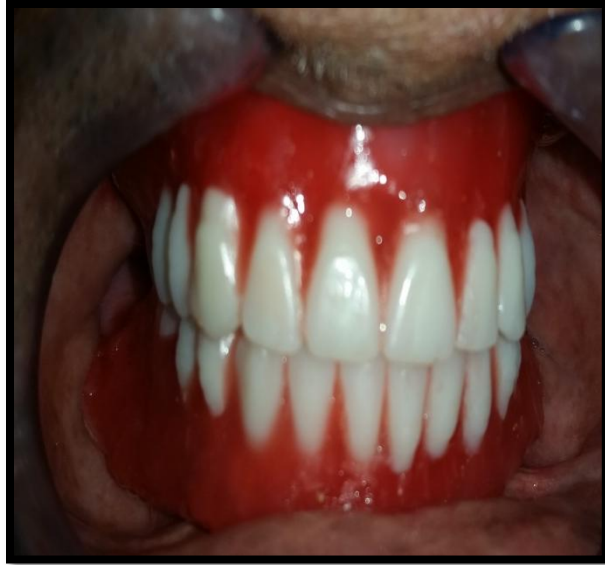

Figure7: Try in done

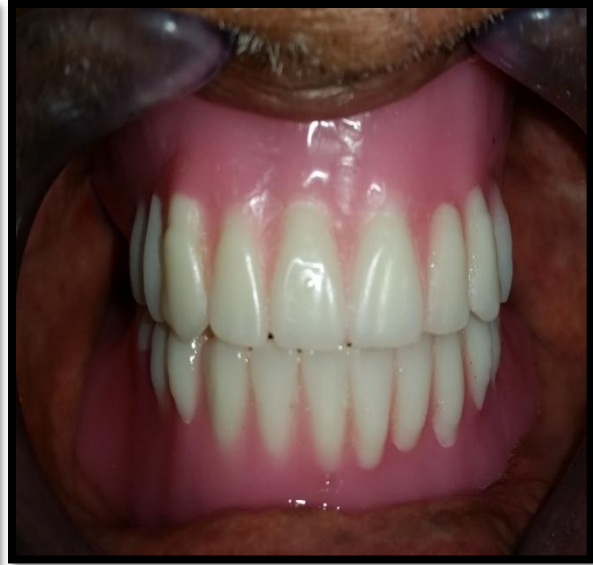

Figure8: Denture insertion



Figure9: Preoperative



Figure10: Post operative

## **Discussion:**

### Denture base :

The part of a complete or removable partial denture which rests upon the basal seat and to which the teeth are attached.”- GPT-8

### Metal base :

The metallic portion of the denture base forming a part or all of the basal surface of the denture .It serves as a base for the attachment of the resin portion of the denture base and the teeth. GPT-8

Postic SD<sup>7</sup>, conducted a study on design of complete denture reinforced with metal base. The study included 116 edentulous patients who received complete dentures. They were divided into two groups according to the type of denture used. Thirty one patients were rehabilitated with complete dentures reinforced with metal base, whereas 85 patients received conventional complete acrylic dentures. Metal bases were fabricated using Co-Cr-Mo alloy. Two designs different in regards to the vibrating line were fabricated: metal frame extended to the vibrating line and acrylic resin extended to the vibrating line. The design of upper denture where metal frame was extended to the vibrating line were the most favored and successful in prosthetic rehabilitation of experimental group of edentulous patients.<sup>7</sup>

In this study metal base was not extended till the vibrating line but acrylic resin base extended till vibrating line which shows favoured and successful rehabilitation of edentulous patient with metal denture base with regular follow-up period.

Anthony De Furio and Daniel H. Gehl (1970) conducted a study to determine the amount of force required to dislodge maxillary dentures made from aluminum, gold and acrylic resin. He used a precision machine to measure the force necessary to dislodge a maxillary denture base from its basal seat. He concluded that the chrome cobalt and aluminum alloy bases gave retention values which were significantly higher than those obtained with the acrylic resins and gold alloy bases.<sup>8</sup>

**Ideal requirements of a denture base material<sup>9</sup>:**

- Bio-compatible
- High flexural and impact strength
- Long fatigue life
- High abrasion resistance
- High thermal conductivity
- Low density
- Low solubility and sorption to oral fluids

**Advantages of cast metal denture bases over acrylic bases:**

- Lack of bulk with more strength
- The metal base prevents warpage during processing.
- Stronger and are less subject to breakage.
- More accurate fit and more faithful reproduction of tissue details.
- Less tissue changes occur under metal bases.
- Dimensional accuracy.
- Less porous.
- Better thermal conductivity
- Show less lateral deformation in function.

Besides rigidity and fracture resistance these metal bases have several other advantages like excellent strength to volume ratio, good adaptation to the supporting tissues, enhanced plaque control, high thermal conductivity, high biocompatibility, very little dimensional changes in time through fluids absorption, does not interfere with phonation due to its decreased bulk which also makes the denture light weight.<sup>10</sup>

The major disadvantages associated with these denture bases include increased cost, difficulty in fabrication, difficult to rebase.<sup>11</sup> Nevertheless; they may be indicated when polymer-based systems fail to provide acceptable physical properties.

**Conclusion:**

The dentist should possess sufficient knowledge of the properties of different Prosthodontics materials they deal with, so that they can exercise prudent judgment in their

selection, which in turn will ensure treatment efficacy and effectiveness. The treatment modality of maxillary metal base and opposing natural dentition provided great comfort to the patient as the metal denture base was strong to resist catastrophic failure solving patients chief complain of recurrent fracture in addition the metal denture bases are good thermal conductors and less bulky thus patient perceive natural feeling from thin base which may also contribute to additional denture stability.

#### **REFERENCES:**

1. Anusavice KJ. Phillips' science of dental materials.10<sup>th</sup>ed, Philadelphia: W.B. Saunders;1996.page no237-72.
2. Lamb DJ, Ellis B, van noort R. The fracture topography of acrylic dentures broken in service .Biomaterials 1985;6:110-2.
3. Darbar UR, Hugget R, Harrison A. Denture fracture-a survey.Br Dent J 1994;176:342-5.
4. Jagger DC,Harrison A,Jandt KD. The reinforcement of dentures. J Oral Rehabil 1999;26:185-94.
5. Zarb GA, Bolender CK, Hickey JC, Carlsson GE. Boucher's Prosthodontic treatment for edentulous patients. 10th ed. St.Louis: C.V. Mosby;1990.P.473-4.
6. El Ghazali S,Glantz PO,Strandman E,Randow K, On the clinical deformation of Maxillary complete dentures. Influence of denture base design and shape of denture bearing tissue. ActaOdontol scand.1989;47:69-76.
7. Postic SD . Design of Complete Denture Reinforced with Metal Base .Serbian Dental Journal, vol. 60, No 1, 2013;15-20.
8. De Furio A. and Gehl. DH : Clinical study of the retention of maxillary complete denture with different DBM . JPD 1970 ,23:374.
9. Atwood D.A : Final report on the clinical requirement of ideal denture base materials .JPD 1968,20 :101.
10. French FA. The problem of building satisfactory dentures. J Prosthet Dent.1954;4:769-81.
11. Faber B. L: Lower cast metal base JPD1957; 51-4.



12. Atwood D.A : Final report on the clinical requirement of ideal denture base materials .JPD 1968,20 :101.
13. French FA. The problem of building satisfactory dentures. J Prosthet Dent.1954;4:769-81.
14. Faber B. L: Lower cast metal base JPD1957; 51-4.